

Antonio Alcaraz

Barna Clinic
Barcelona, Spain

CLINICAL CASE 2

Male 58 yo

BMI: 26

PS: 0

Medical History

Abdominal exploration (Stab wound -1976)

Mild coronary stenosis

Dyslipidemia

Treatment: Simvastatin, Aspirin (will be stopped 5 day before surgery)

CLINICAL CASE 2

PSA: 22 ng/ml

MRI:

- Right Lesion PIRADS 5/5
- T3b (doubt on SVI) N0
- Prostate volume : 28 g

Biopsy: Adenocarcinoma

10+/ 12 core biopsy (77/ 147 mm)

Perineural extension+ Extracapsular extension -

CLINICAL CASE 2

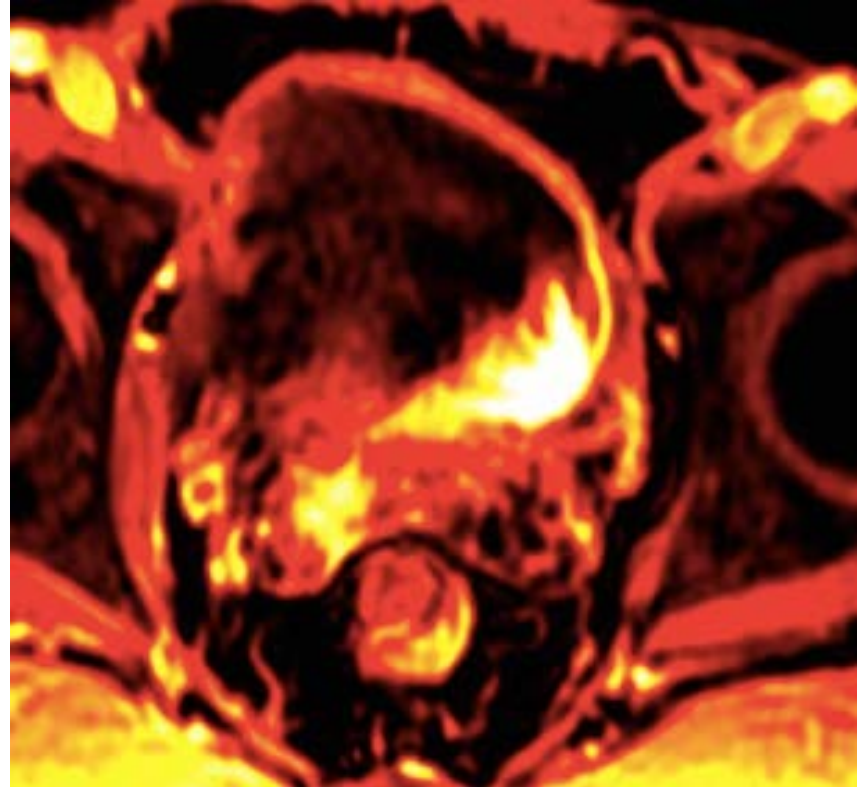
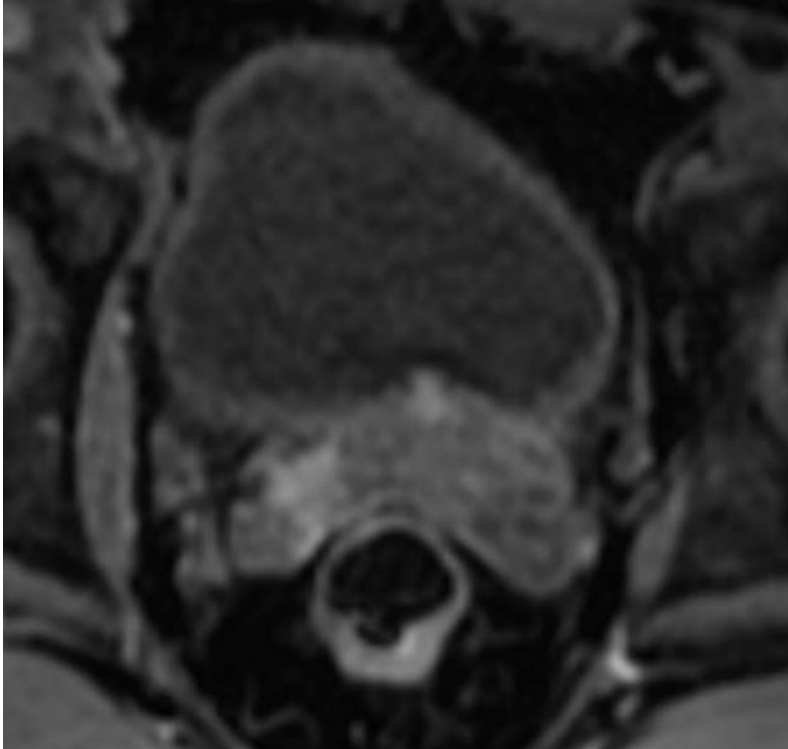
PET-MRI

Right lesion: T3a-b N0 M0

Bone scan –

CT Scan -

CLINICAL CASE 2



CLINICAL CASE 2

